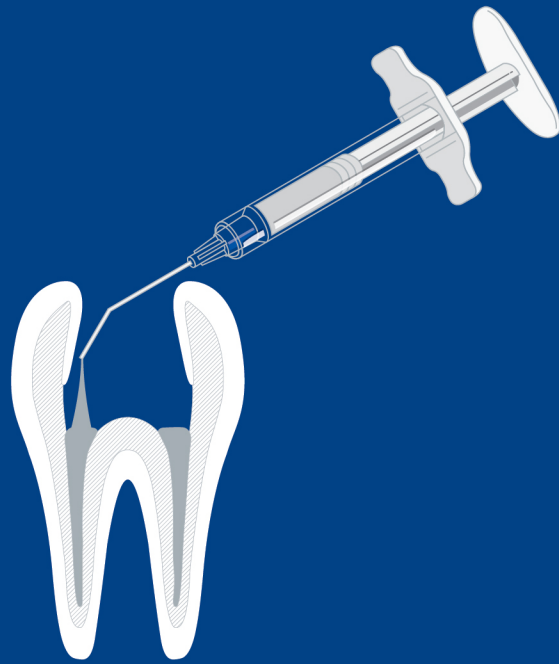

ENDOSEAL MTA

Premixed Injectable Sealer



Simple · Smart · Safe



ENDOSEAL MTA

Premixed Injectable Sealer

MARUCHI

Main Office
2-208, 42-10, Taejanggongdan-gil, Wonju-si, Gangwon-do, Korea 26311

T +82-33-734-0330 F +82-33-746-2804

E info@endocem.com



YOGI ENTERPRISES

www.kidscrown.in

+91 9820077793 +91 9029077793

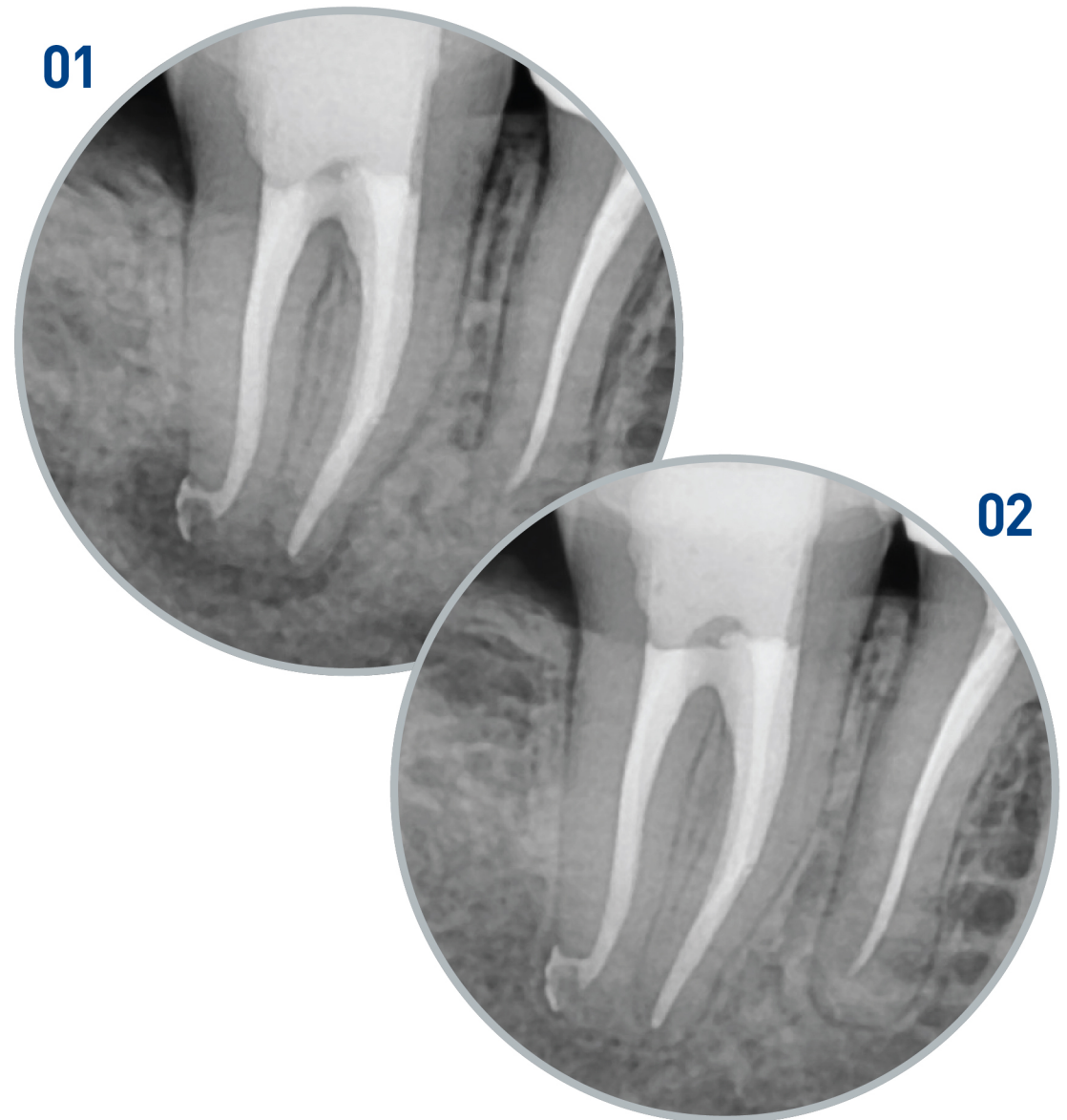
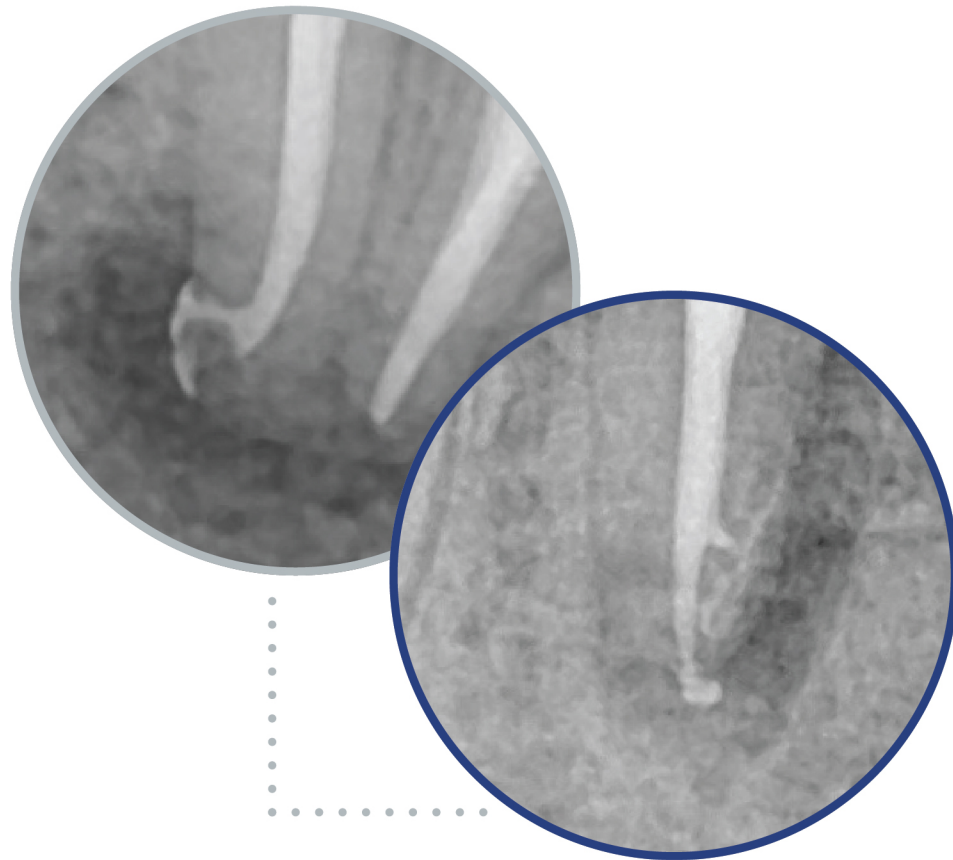


ENDOSEAL MTA

01 Endoseal MTA


Science & Technology	04
Biocompatibility	06
Hermetic sealing	08
Biomineralization	09
Hard tissue formation I	10
Hard tissue formation II	12
Antibacterial effect	14
Physical properties of Endoseal MTA	14

01 Science & Technology



The inside of the root canal system has high humidity due to residual moisture in the dentinal tubules. MTA solidifies into a hard structure by absorbing the moisture from the surrounding tissue and has outstanding sealing capacity and biocompatibility. Therefore, it is appropriate for root canal treatment. **Endoseal MTA** solidifies by absorbing the moisture from the surrounding tissue and producing calcium hydroxide during the process that penetrates into the dentinal tubules, and it creates hydroxyapatite extensively. In addition, it induces regeneration of the surrounding damaged hard tissue.

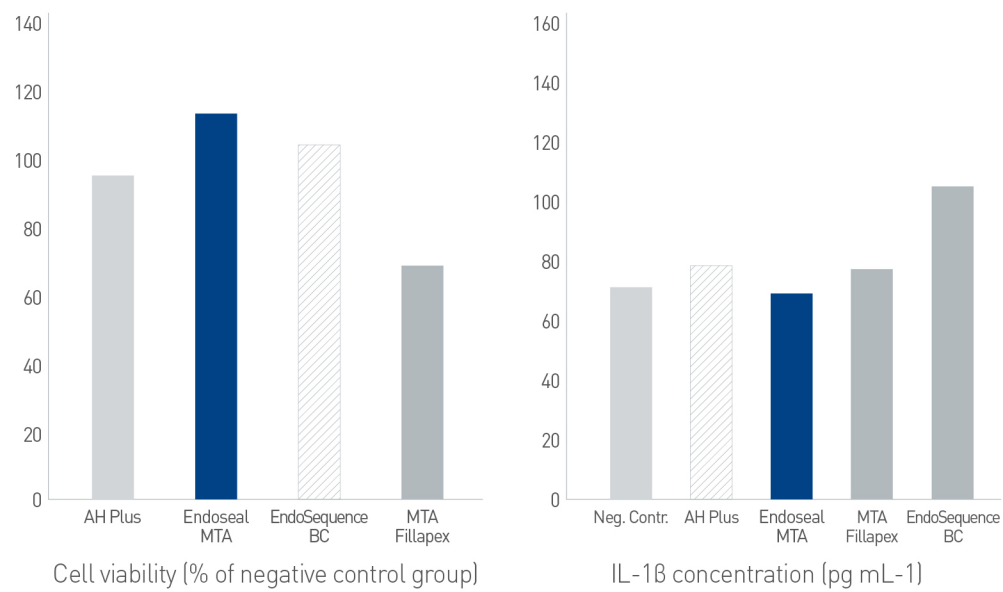
02 Biocompatibility



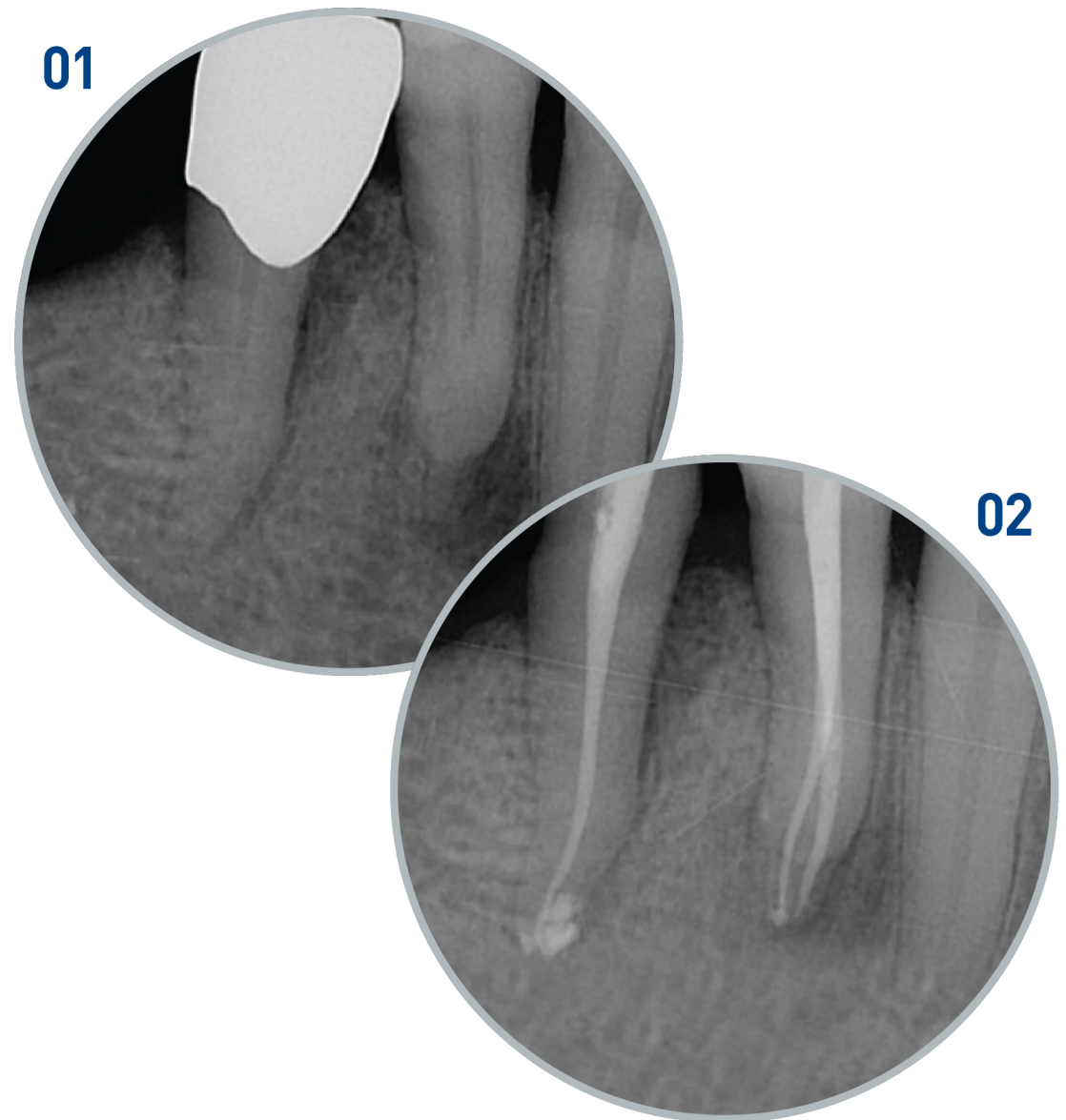
Lim et al. BMC Oral Health (2015) 15:129

Since Endoseal MTA is a root-end filling material based on MTA, it has superior biocompatibility and little inflammation. These characteristics of Endoseal MTA have been verified by many researchers and published at SCI journals.

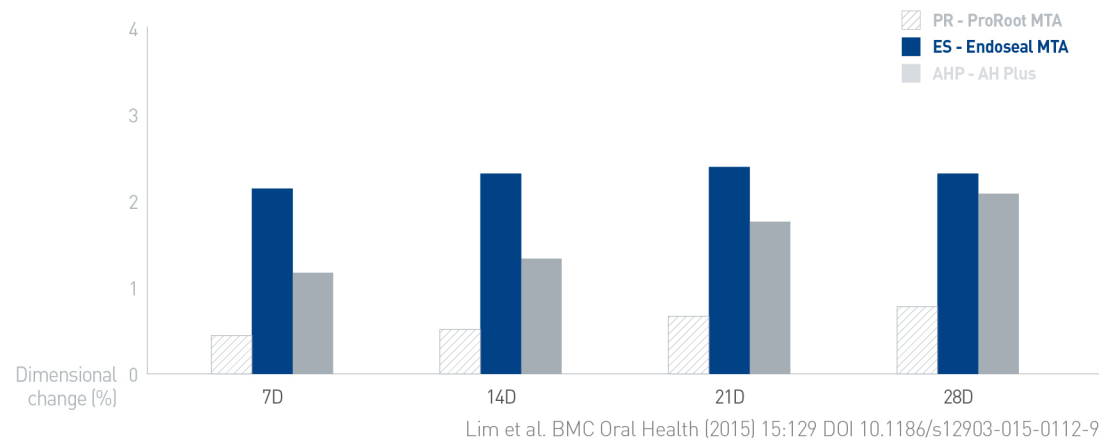
Cytocompatibility of calcium silicate-based sealers in a three-dimensional cell culture model



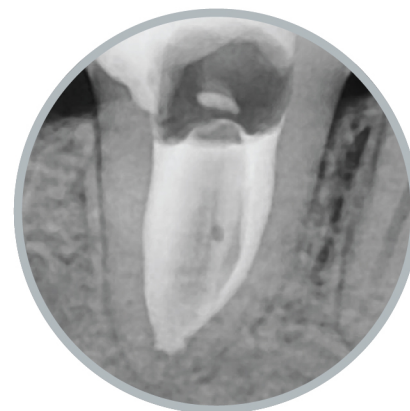da Silva, E.J.N.L., Zaia, A.A. & Peters, O.A. Clin Oral Invest (2016). DOI 10.1007/s00784-016-1918-9



03 Hermetic sealing

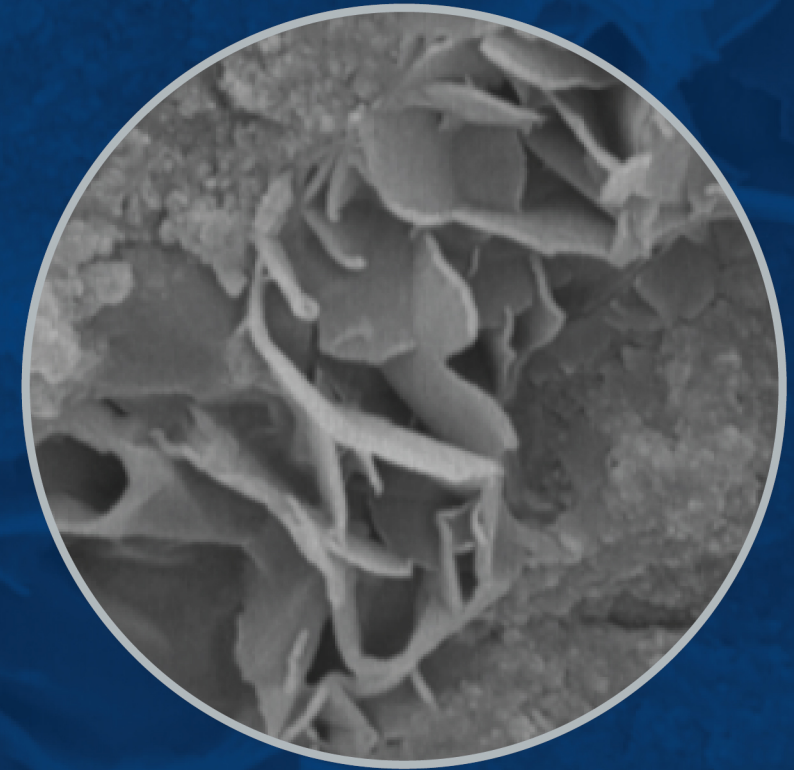

2% dimensional change of Endoseal MTA occurs only during setting process. Afterward it rarely expands as shown in the table. In addition, Endoseal MTA is naturally penetrated even into unreachable spaces, where a dentist could not fill, during complete hardening time (12 hours).



It is easy and fast to obturate the complex root canal system

04 Biomineralization



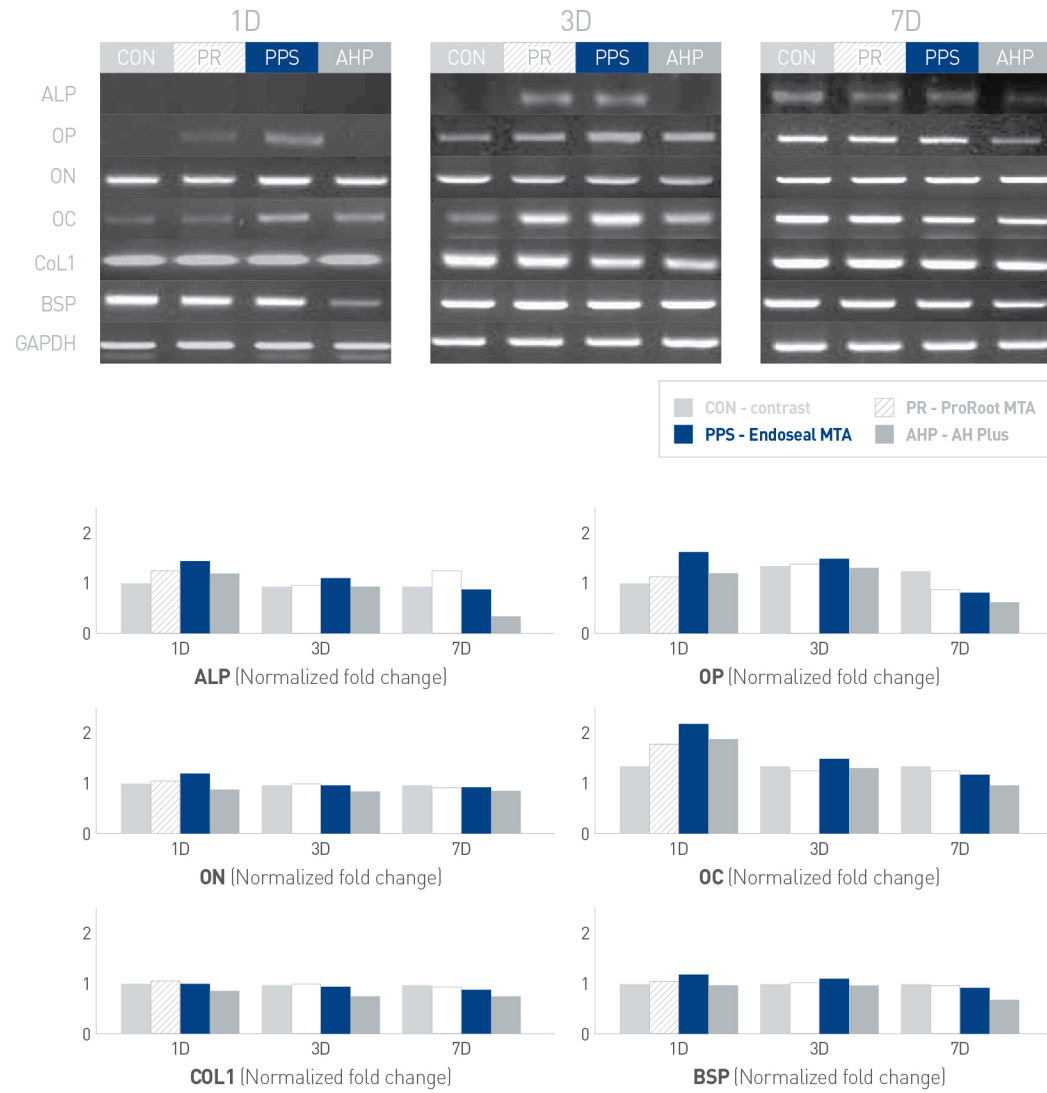
Lee et al. Scanning. 2016 Jan-Feb;38(1):50-6

Dynamic Intratubular Biomineralization Following Root Canal Obturation With Pozzolan-Based Mineral Trioxide Aggregate Sealer Cement

Root canal obturation material	Depths of material penetration into the dentinal tubule and intratubular mineralization (mean ± standard deviation)		
	GP with Pz-MTA sealer	Pz-MTA sealer only	ProRoot MTA only
Tubular penetration depth (µm)	23.77 ± 2.48	Not detected	Not detected
Intratubular Mineralization depth (µm)			
PBS pretreatment			
- NO	350.25 ± 36.50 ^{Ab}	62.55 ± 9.56 ^{Bb}	68.20 ± 11.20 ^{Bb}
- YES	392.69 ± 39.43 ^{Aa}	98.12 ± 14.45 ^{Ba}	130.51 ± 20.21 ^{Ba}

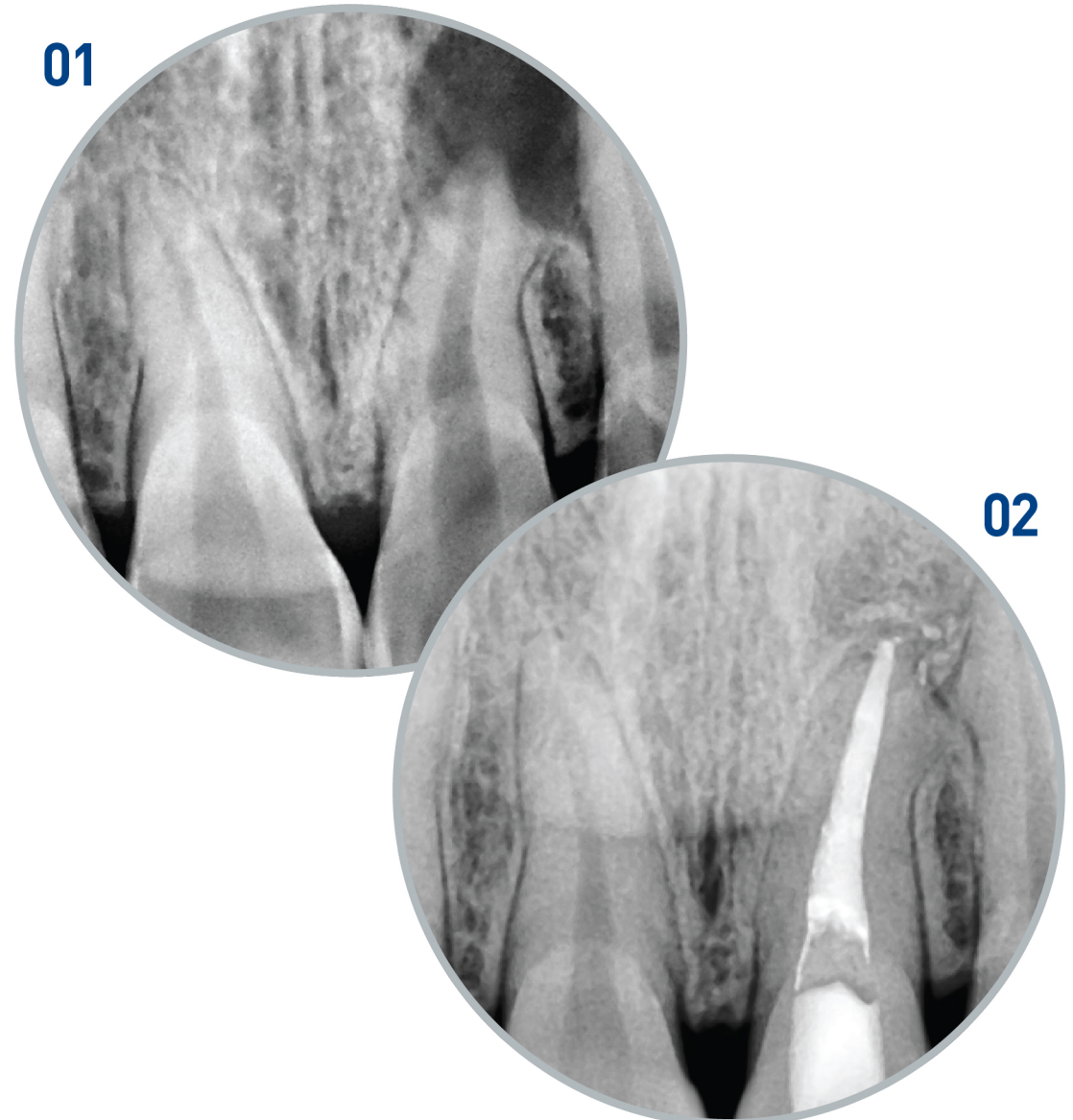
GP, gutta percha; MTA mineral trioxide aggregate; PBS, phosphate buffered saline; Pz-MTA, pozzolan-derived mineral trioxide aggregate. Same uppercase alphabet superscripts in row show no significant differences among the mean values of experimental groups (p > 0.05). Same lowercase alphabet superscripts in column show no significant effect of PBS pretreatment on the mean values of intratubular mineralization within each group (p > 0.05).

05 Hard tissue formation I

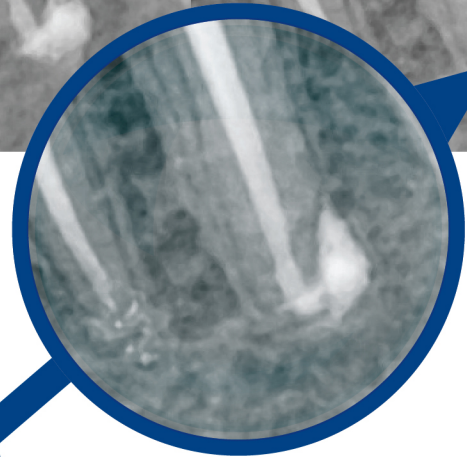
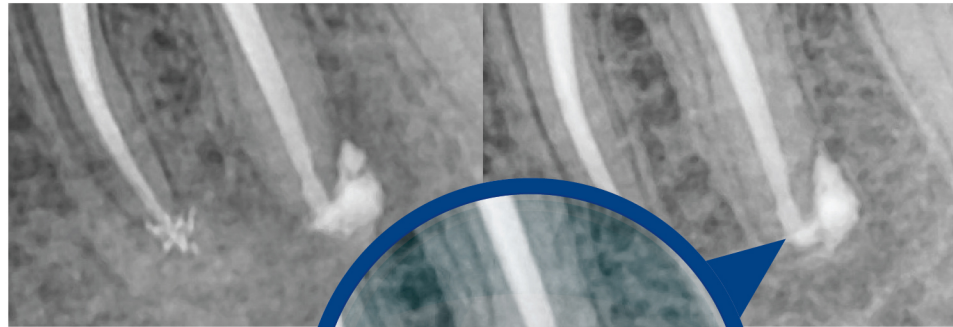


Endoseal MTA shows an increased gene expression involved in hard tissue formation, and the phenomenon induces a rapid healing of the periapical lesion.

Endoseal MTA not only has excellent sealing ability, but also promotes hard tissue formation around the infected tooth. The superior ability of the hard tissue formation can be seen by various genetic tests.

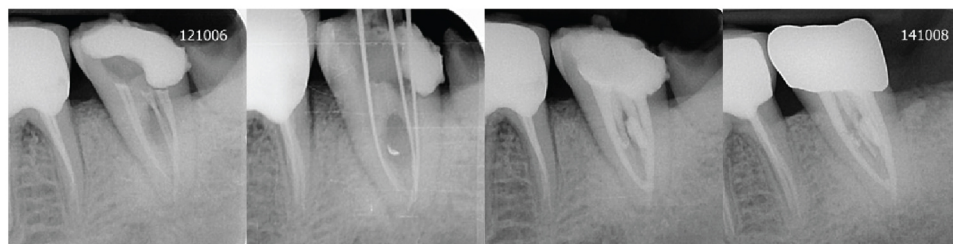
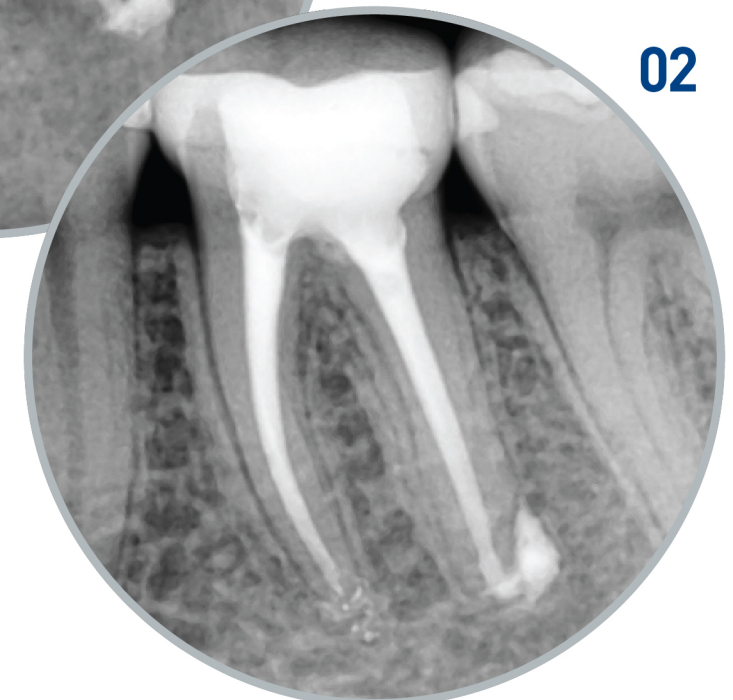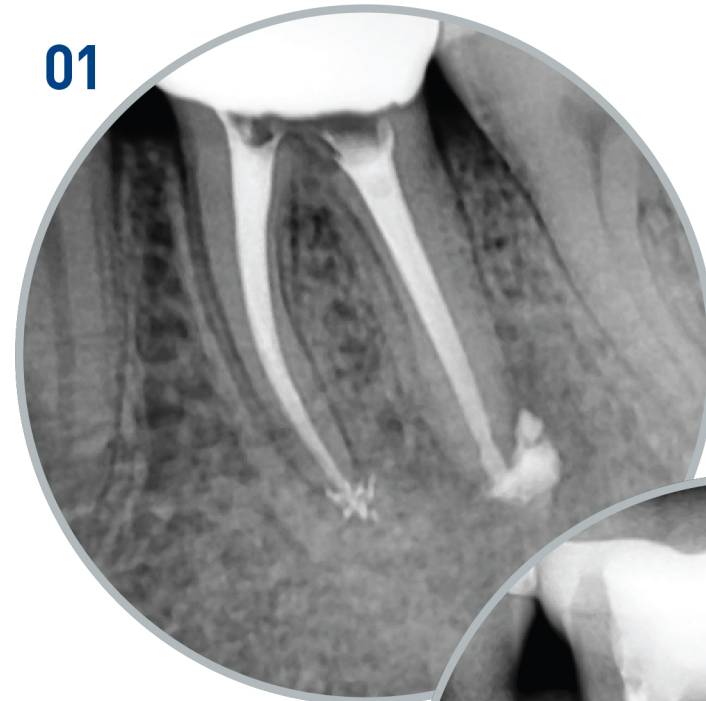


05 Hard tissue formation II



Based on the comparison between the early postoperative and 13-month postoperative radiographs, well-developed hard tissues are shown.

It is observed that lamina dura around Endoseal MTA is well developed, whereas AH Plus situated in the mesial root canal is absorbed.



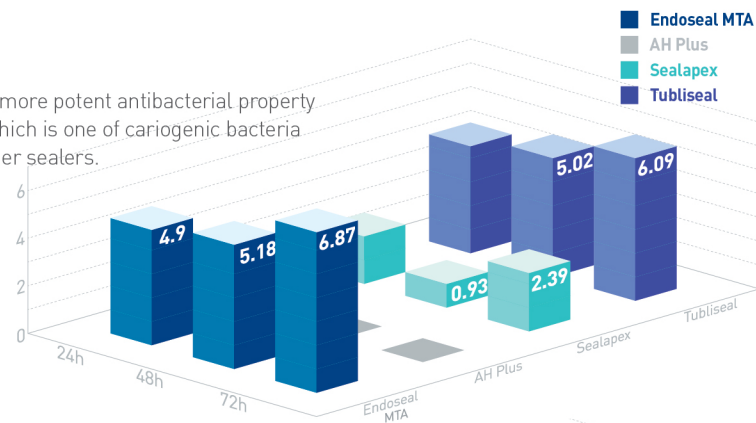
These images show that stable healing occurs 2 years after Endoseal MTA is used in strip-perforations.

06 Antibacterial effect

Endoseal MTA has a high PH and excellent antibacterial effects. E. faecalis, which is most commonly observed in the teeth whose endodontic treatment fails, is very difficult to control with conventional intracanal instruments and cleansing, and is resistant to intracanal medicament. If a root canal sealer has antibacterial effects against E. faecalis, the root canal treatment will have higher predictability.

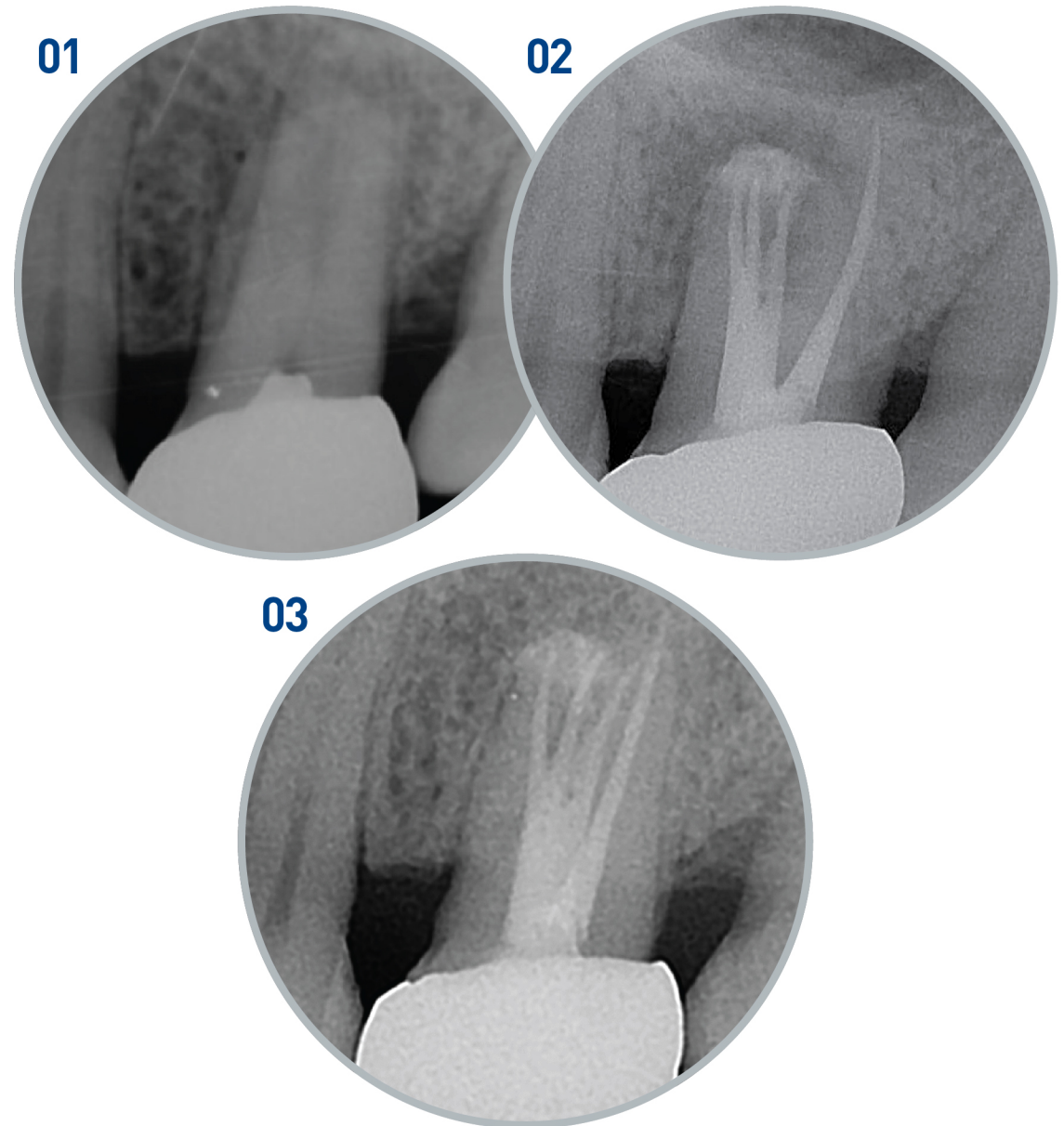
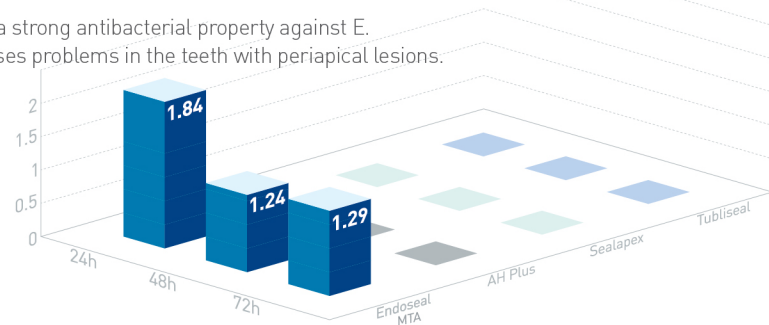
S. Mutans

Endoseal MTA has a more potent antibacterial property against S. Mutans, which is one of cariogenic bacteria species, than any other sealers.



E. Faecalis

Endoseal MTA has a strong antibacterial property against E. faecalis, which causes problems in the teeth with periapical lesions.



07 Physical Properties of Endoseal MTA

	Endoseal MTA	BC sealer	MTA Fillapex	AH Plus
Flow (mm)	34.13	18.45	20.21	21.86
Film thickness (µm)	15	22 ± 4.58	23.92 ± 7.05	16.07 ± 4.5
Setting time (h)	12.31	?	?	11.5 ± 1.5
Solubility (%)	0.7	2.9 ± 0.5	1.10 ± 0.15	0.06 ± 0.04
Radiopacity (mm Al)	9.50	6.68	3.01	10.00

Since some materials were not eventually solidified despite several attempts to measure setting time, ? is indicated on the table above.



ENDOSEAL MTA

02 FAQ

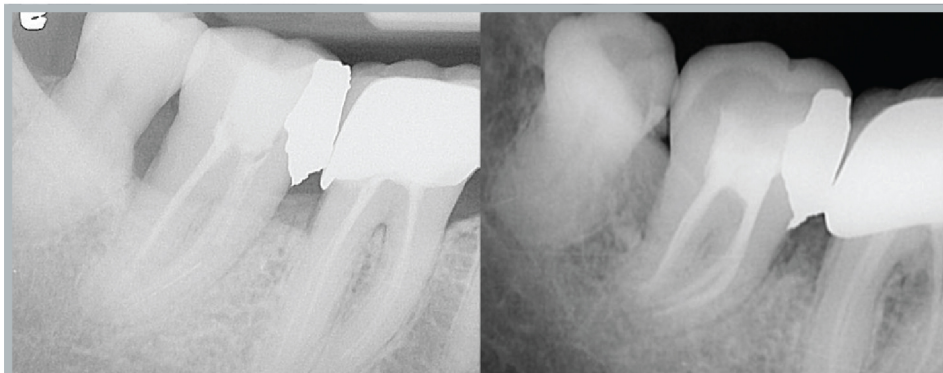
What application method is acceptable?	18
What kinds of tip should be used?	18
How deep should the tip be inserted?	19
Endoseal MTA went beyond the apex.	20
What is the process for the one-day core and post?	20
The master cone is not reaching to the root canal apex.	21
Can it be used in the anterior teeth?	22
Can it be used on deciduous teeth?	23
Can it be removed at a later time?	26
Can it be used in immature permanent teeth?	27
The entrance of the syringe is blocked.	27
How to Keep Endoseal MTA better?	27

FAQ What application method is acceptable?

- 01 For the convenience of obturation, the single cone technique can provide sufficient sealing effects.
- 02 In case of the root canal with excessive enlargement or wide shape, accessory cones can be additionally inserted in order to reduce bubble formation.
- 03 Vertical pressurization increases the viscosity of Endoseal MTA, reduces bubble formation, and helps Endoseal MTA to penetrate deeper into the dentinal tubules.
- 04 The ultrasonic condensation technique is the most delicate technique as stated in IFU and it has less bubble formation.

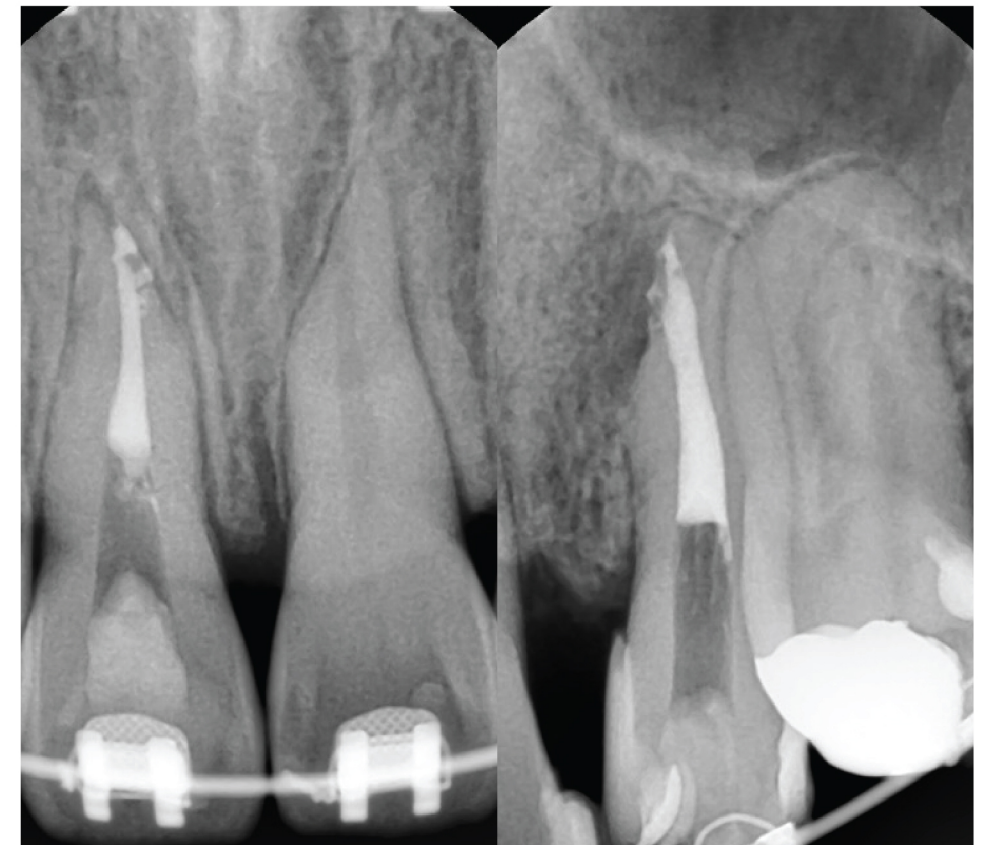
FAQ What kinds of tip should be used?

- 01 It is recommended to use a beveled 24-gauge metal tip. Since Endoseal MTA is pushed to the side, there is little possibility of an excessive injection beyond the root apex. Therefore, it is safe to use.
- 02 For root canal filling of deciduous teeth, a plastic tip, such as Vitapex, should be used.
- 03 If there are obstacles (e.g., broken file in the root), insert the plastic tip directly above the obstacle, and then fill with strong pressure.



Tightly place the plastic tip directly above the broken file and strongly dispense paste until the patient feels pain.

FAQ How deep should the tip be inserted?



Endoseal MTA has a small contact angle and a distinctive characteristic of increasing viscosity when pressurized. Therefore, it easily fills the root apex without deeply inserting the tips and squeezing.

You do not need to insert the tip deeply into the root canal length. Since Endoseal MTA has a low contact angle and its viscosity increases when pressurized, it can be easily dispensed into the root apex even in case of elongated root canals.

Hence, after injecting Endoseal MTA into the center of the root canal, it is sufficient to just insert the master cone slowly so that Endoseal MTA penetrates into the root apex. If the tip is tightly fitted in the root canal, you must pay special attention to dispense Endoseal MTA because a large amount of paste may overflow beyond the root canal.


FAQ Endoseal MTA went beyond the apex.

- 01 In case of the root canal without apical stop or with lesions, you must smoothly insert the master cone by neither applying vibration nor pumping.
- 02 Although Endoseal MTA goes beyond the root apex, it does not irritate the root apex or cause lesions. Because, even though time passes, Endoseal MTA is usually not absorbed due to hard tissues formed around the overflowed Endoseal MTA.
- 03 If nerves run beneath the root apex, special attention should be taken not to pass beyond the root apex.

FAQ What is the process for the one-day core and post?

- 01 To create a core for the one-day treatment, cut the master cone at the orifice of the root canal and then compress it with a condenser to seal it.
- 02 Afterward, thoroughly clean with water and perform conventional etching and bonding.
- 03 To create a post for the one-day treatment, cut the master cone as much as you want by using the ultrasonic tip or vertical compaction instrument, compress it, and then seal with a GP cone. After that, proceed with conventional etching and bonding.
- 04 If you need to build up a post at next appointment, follow conventional methods.

FAQ The master cone is not reaching to the root canal apex.

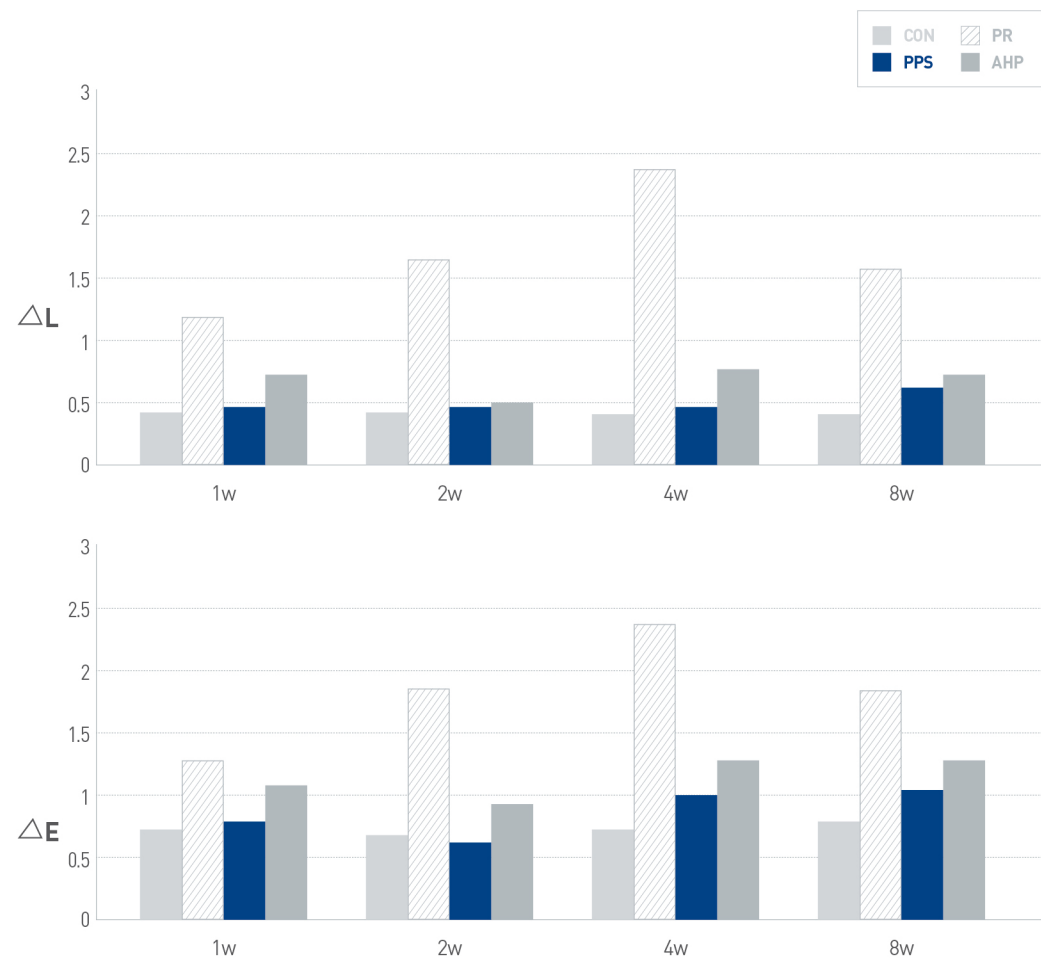


Biom mineralization The image shows Endoseal MTA inside the root canal was diffused into the surrounding dentinal tubules.

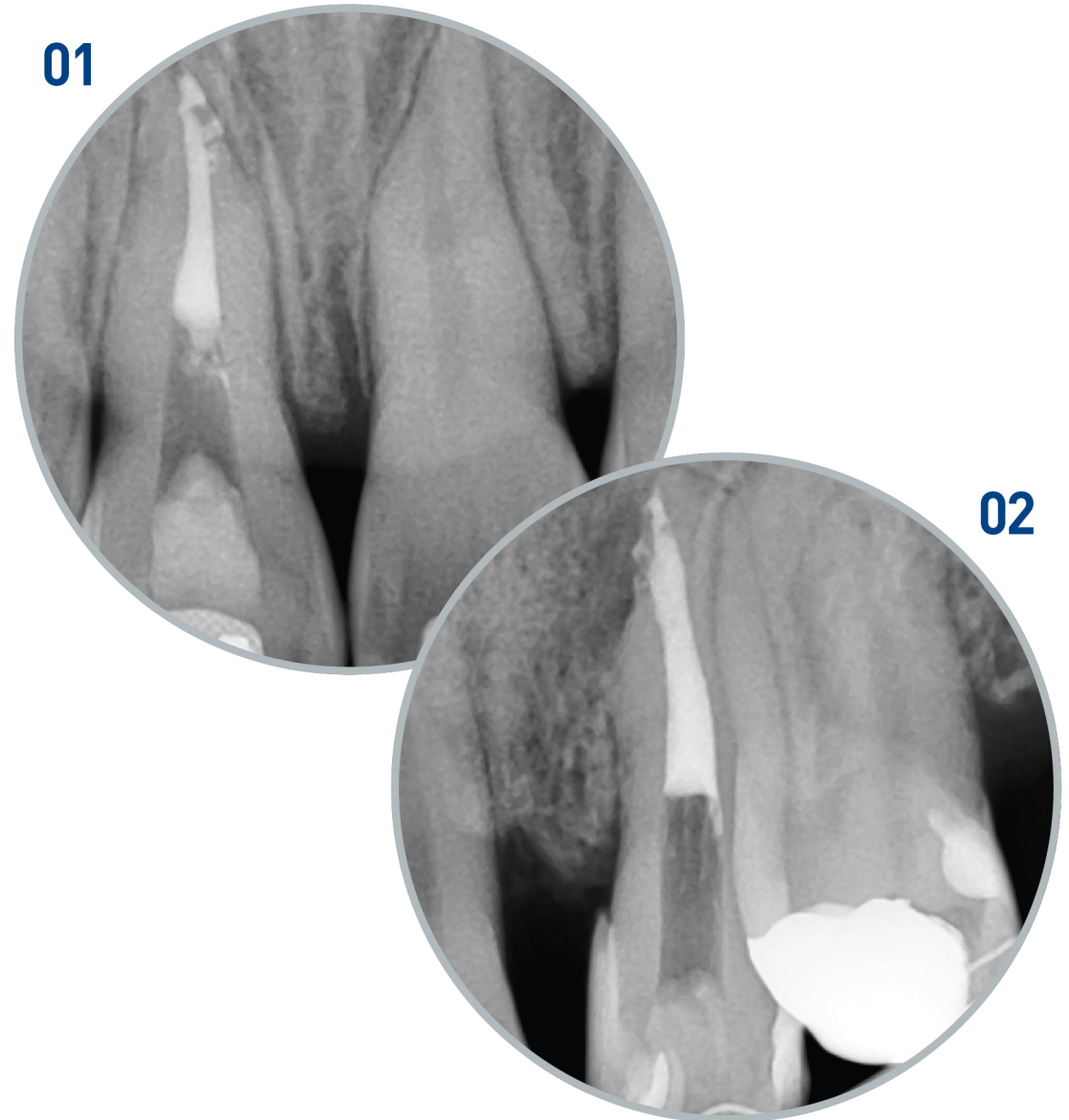
Rapidly increased viscosity makes Endoseal MTA diffused into not only the root apex but also the complex anatomical structures (e.g. accessory canal and dentinal tubule), so it helps to produce better sealing and healing performance. For the master cone, non-standard GP cone is recommended to use. And it is better to feel the tug-back in the middle third of the root canal than the apical third.

FAQ Can it be used in the anterior teeth?

Endoseal MTA uses the pozzolanic reaction internationally patented. Therefore, it does not discolor the tooth even though containing bismuth oxide. Since free silica ingredient forms hydrous calcium silicate by reacting with calcium hydroxide created during the process of solidification, it prevents tooth discoloration.

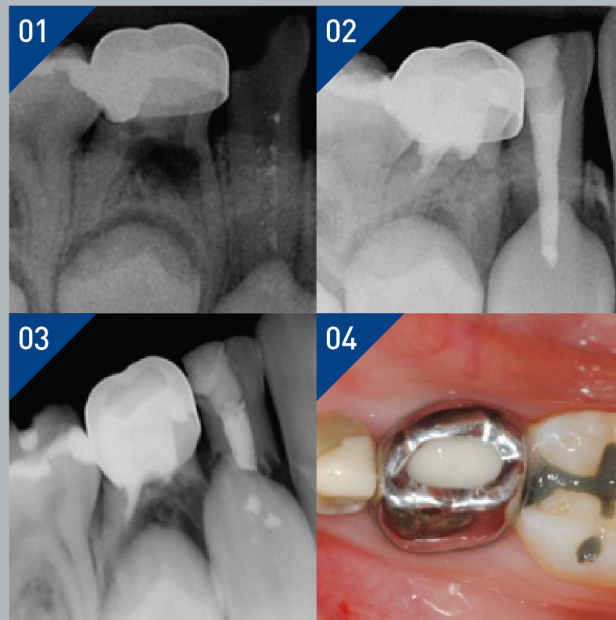


Lee et al. Tooth discoloration induced by a novel mineral trioxide aggregate based root canal sealer. Eur J Dent 2016;10:403-7. DOI: 10.4103/1305-7456.184165



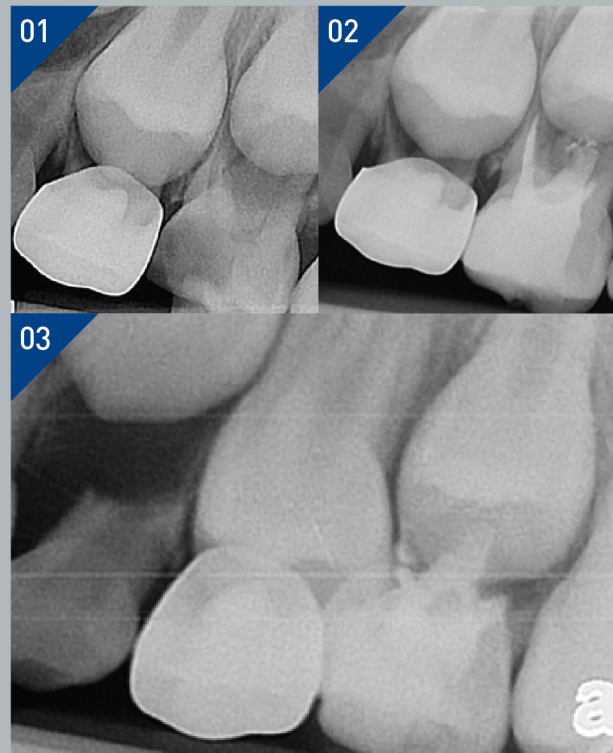
FAQ Can it be used in deciduous teeth?

○ CASE 1



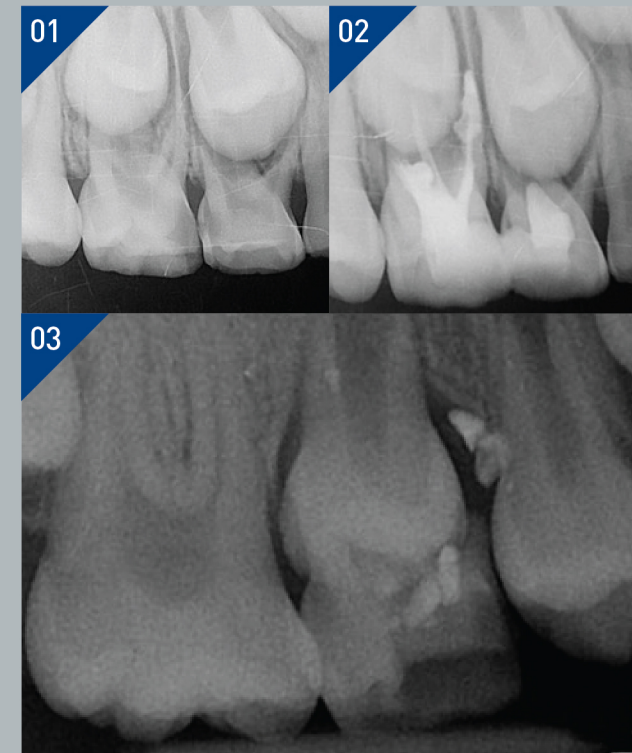- 01 In case of the deciduous teeth, Endoseal MTA must be used only by it-self in order to be naturally absorbed as the root of deciduous tooth. It must be never used with GP cone.
- 02 In case of endodontic treatment for the deciduous teeth, if sealing the accessory canal by applying Endoseal MTA onto the bottom of the pulp chamber as at least 2-mm thickness, it can yield more predictable results.
- 03 If there is a furcation defect, a permanent tooth eruption is faster than an alveolar bone regeneration resulting from effects of MTA. Therefore, you must inform the guardian of the possibility of early eruption.

○ CASE 2



In case of root perforation having lesions, Endocem MTA, which has more faster setting time, was used instead of Endoseal MTA, however a deciduous canine adjacent to the surrounding was filled with Endoseal MTA. After a year, the natural eruption of the permanent tooth and absorption of Endoseal MTA were observed.

○ CASE 3

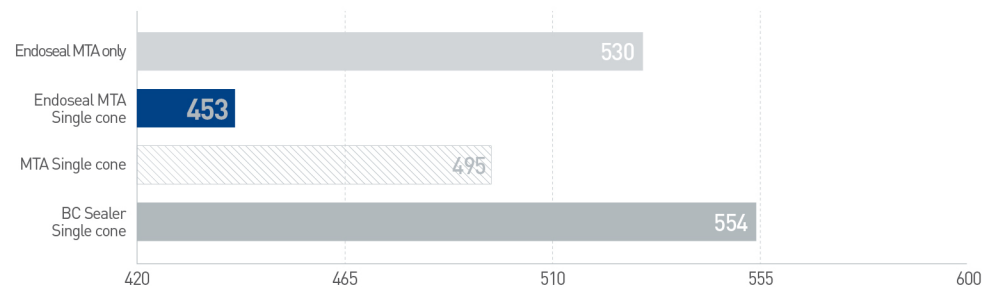


This is common case of pulpectomy by Endoseal MTA and pulpotomy by Endocem MTA. In case of a deciduous tooth with a furcation defect, the eruption of the follow-up permanent tooth occurs earlier than the alveolar bone regeneration, even after a complete healing. A naturally absorbed Endoseal MTA has been observed.

FAQ Can it be removed at a later time?

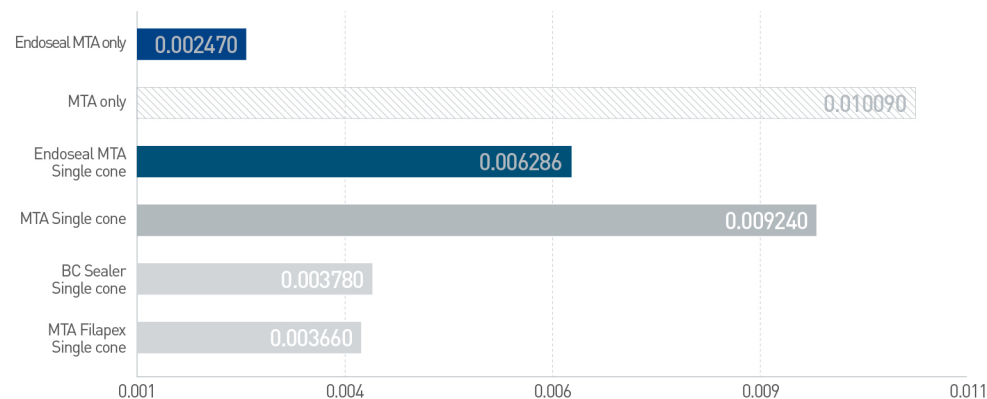
- 01 Since Endoseal MTA contains enough zirconia, Endoseal MTA can be removable anytime even after solidification. (Obtain relevant international patent)
- 02 If retreatment is required, Endoseal MTA can be removed by using a general hand file or Ni-Ti file.

Retrievability 01



Root canal filling material should be removable. It takes much less time to remove Endoseal MTA than other root canal fillers.

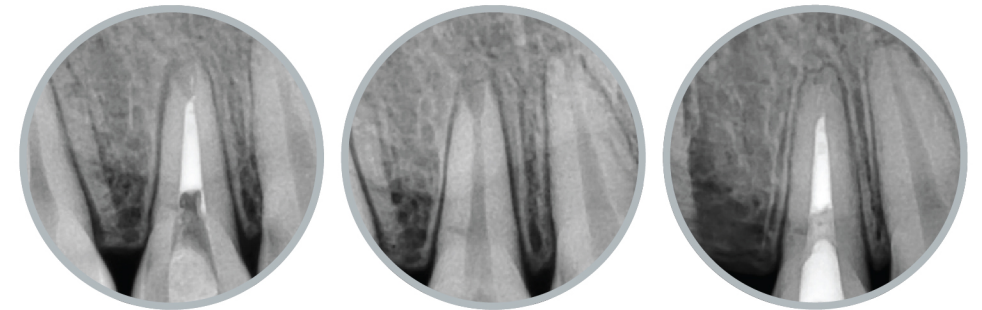
Retrievability 02



The table shows results of test conducted to compare the residual quantity after removal. Only small amount of Endoseal MTA is left in the root canal after removal.

FAQ Can it be used in immature permanent teeth?

- 01 Endoseal MTA has exact same advantages of MTA. Hence, applications for both root perforation and immature permanent teeth yield predictable results.
- 02 In case of immature permanent teeth in which the inside of the root canal is filled with blood, it is recommended to use Endocem MTA.



These images show the radiographs 17-month after Endoseal MTA is obturated in the root canal of immature permanent teeth with open apex.

FAQ The entrance of the syringe is blocked.

- 01 Endoseal MTA has a strong hygroscopic property.
- 02 You must never reuse the plunger cap of the syringe. Instead of it, the tip, which you used for the treatment, must be kept without removal. In this case, it is safer to reinstall the used tip's cap.
- 03 Just prior to next application, you replace the unremoved tip with new one.

FAQ How to keep endoseal MTA better?

It is recommended to store Endoseal MTA at temperature above 20 °C in order to maintain its flowability.